

Hypospermatogenesis and Spermatozoa Maturation Arrest in Rats Induced by Mobile Phone Radiation

Sultan Ayoub Meo¹, Muhammad Arif², Shahzad Rashied³, Sufia Husain⁴, Muhammad Mujahid Khan³, Muhammad Saeed Vohra³, Adnan Mahmood Usmani⁵, Muhammad Babar Imran⁶ and Abdul Majeed Al-Drees¹

ABSTRACT

Objective: To determine the morphological changes induced by mobile phone radiation in the testis of Wistar albino rats.

Study Design: Cohort study.

Place and Duration of Study: Department of Physiology, College of Medicine, King Saud University, Riyadh, Saudi Arabia, from April 2007 to June 2008.

Methodology: Forty male Wistar albino rats were divided in three groups. First group of eight served as the control. The second group [group B, n=16] was exposed to mobile phone radiation for 30 minutes/day and the third group [group C, n=16] was exposed to mobile phone radiation for 60 minutes/day for a total period of 3 months. Morphological changes in the testes induced by mobile phone radiations were observed under a light microscope.

Results: Exposure to mobile phone radiation for 60 minutes/day caused 18.75% hypospermatogenesis and 18.75% maturation arrest in the testis of albino rats compared to matched controls. However, no abnormal findings were observed in albino rats that were exposed to mobile phone radiation for 30 minutes/day for a total period of 3 months.

Conclusion: Long-term exposure to mobile phone radiation can cause hypospermatogenesis and maturation arrest in the spermatozoa in the testis of Wistar albino rats.

Key words: *Hypospermatogenesis. Maturation arrest. Testis. Albino rats.*

INTRODUCTION

The appearance and evolution of mobile phones is one of the fastest in the history of innovation.¹ More than two-third of the world population is using this technology.² The newly industrialized and developing countries are outstanding in fast growth of use of mobile phones. Pakistan had a total of 98 million mobile phone users as stated in May 2010.³

The mobile phones and cell towers generate electromagnetic field radiation (EMFR) and have become a frequent source of the contamination of the human environment by producing non-ionizing radiation.⁴ Mobile phones are transmitting radio frequency radiation at 900-2000 MHz.^{5,6} Analog phones operate at 450-900 MHz, digital phones [Global System for Mobile Communications, GSM] at 850-1900 MHz, and third-generation phones at approximately 2000 MHz.⁷ EMF radiation generated by mobile phones can inflict their results through both thermal and non-thermal effects.⁸

Exposure of EMFR depends upon the frequency of the cellular phone used. The higher the frequency, greater the chances of carrying more radiant energy, which is absorbed into the human body by three main mechanisms: (i) aerial effect: body receives and absorbs the RF signal depending upon size of the body part and wavelength of signal (ii) coupling of the RF signal with the tissue and (iii) resonant absorption.⁹ This phenomenon has raised concerns about the possible hazards of mobile phone radiation on human health.^{10,11} Mobile phones are mainly placed in the side pockets or hung with belt near to the reproductive structures including testes. There is some evidence to suggest that exposure to mobile phone radiation may affect the reproductive function and their morphological features.¹² Therefore, the present study was conducted to determine the morphological changes induced by mobile phone radiation in the testis of Wistar albino rats.

METHODOLOGY

This cohort study was conducted in the Department of Physiology, College of Medicine, King Saud University, Riyadh, Saudi Arabia, from April 2007 to June 2008. A total of 40 male albino rats (Wistar Strain), 2 months of age, weighing 160-175 gm, with same genetic background, were recruited for the experiment.

Animals were randomly divided into three groups and housed in three cages in a similar environment and were

Department of Physiology¹/Pharmacology²/Anatomy³/ Pathology⁴/ Diabetes Centre⁵/Nuclear Medicine⁶, College of Medicine, King Saud University, Riyadh, Kingdom of Saudi Arabia.

Correspondence: *Prof. Dr. Sultan Ayoub Meo, Professor and Consultant in Clinical Physiology, Department of Physiology, College of Medicine, King Saud University, P.O. Box. 2925, Riyadh 11461, Kingdom of Saudi Arabia.*

E-mail: smeo@ksu.edu.sa

Received August 02, 2010; accepted April 06, 2011.

fed with standard pellet diet [Gold Mohar] and water ad-libitum. They were maintained under controlled temperature of 22-24°C and had 12-12 hours light-dark cycle [light on 06:00-18:00 hour].¹³ The animal experimental protocol was approved by the animal ethics board, College of Medicine Research Centre, King Saud University, and experiment was performed according to the suggested guidelines.

Wistar albino rats (n=40) were randomly divided into three groups. The group A (n=8) served as a control and the remaining 2 groups B and C (n=16 each) were exposed to EMF Radiation generated by mobile phone on a specific time of the day [during light period] for a total period of 3 months. The group B was exposed to mobile phone radiation for 30 minutes daily and group C was exposed for 60 minutes daily for 3 months. In this experiment, Global System for Mobile communications [GSM] handsets of mobile phone of the same brand and model were used. A mobile phone was placed inside the cage and a call was given with another mobile phone. It was ensured that the mobile phone inside the cage was powered-on, and with call accepting [answering] mode and the rats were in close proximity to the mobile phone.¹³

After completion of the mobile phone radiation exposure for the total period of 3 months, the albino rats were scarified the testis were removed for histo-pathological examination. The testes were collected in 10% formalin before they were processed in a tissue processor (vacuum infiltration processor, Tissue Tek VIP). The tissue samples were embedded in paraffin and 5 mm cross-sections was stained with hematoxylin-eosin. All slides were examined under a light microscope by a senior Histopathologist and Anatomist. The tissues were examined for any alterations in normal spermatogenesis such as hypospermatogenesis or maturation arrest. The criterion for the hypospermatogenesis was any appreciable reduction in the number of germ cells with

associated thinning of the multilayer epithelium. As for maturation arrest, it was based on the absence of maturation of the germ cells in the seminiferous tubules from spermatogonia to mature viable spermatozoa. Maturation arrest can be completed in which there is no maturation to spermatozoa or incomplete in which few mature spermatozoa were micro focally present. All the parameters were graded as negative =0; mild=1+; moderate= 2+; and severe =3+.

The morphological findings were entered into the computer. SPSS-17 software program was used and results [findings] were computed based on the total number of cases and the percentage [%] of any abnormal morphological findings in the testis of the Wister albino rats.

RESULTS

The testicular tissue were examined for hypospermatogenesis, Leydig cell changes, sertoli cell changes, testicular blood vessels obliterations, inflammation, maturation arrest and malignancy in the testes of Wistar albino rats.

No abnormal morphological findings were found in the Leydig cell, sertoli cells and testicular blood vessels. And no inflammation and malignancy was seen in the testes of Wistar albino rats exposed to mobile phone radiation. However, in 3 cases [18.75%] hypospermatogenesis was observed and maturation arrest was also seen in 3 cases [18.75%] albino rats that were exposed to mobile phone radiation 60 minutes daily for the total period of 3 months compared to their matched control (Figures 1-3).

Although, no abnormal findings were observed in the testes of albino rats that were exposed to mobile phone radiation for 30 minutes/day for the total period of 3 months.

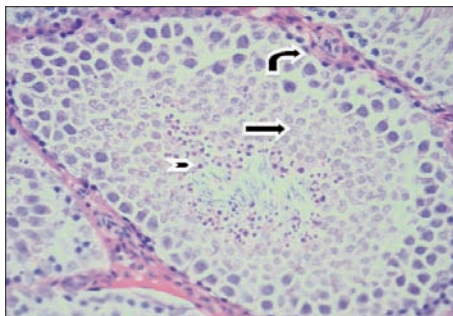


Figure 1: Wister albino rat testis [control group] not exposed to mobile phone radiation [H+E stain, 400 magnifications] shows normal active spermatogenesis. There are sertoli cells, spermatogonia (curved arrow), spermatocytes, spermatids (straight arrow) and numerous mature spermatozoa (arrowhead).

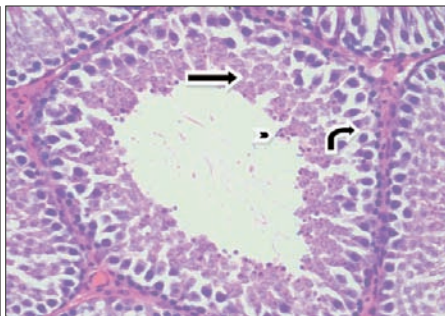


Figure 2: Wister albino rat testis exposed to Mobile phone radiation [H+E stain, 400 magnifications] shows a seminiferous tubule with hypospermatogenesis. There are sertoli cells, spermatogonia (curved arrow), spermatocytes, spermatids (straight arrow). There is however a significant reduction in the number of mature spermatozoa (arrow head).

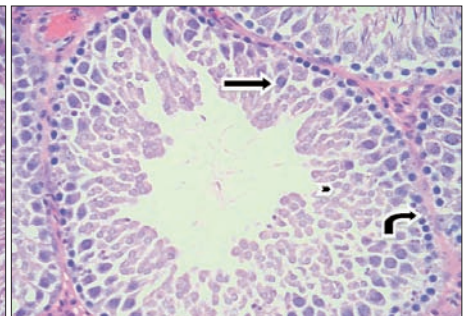


Figure 3: Wister albino rat testis exposed to mobile phone radiation [H+E Stain, 400 magnifications] shows features of incomplete spermatid maturation arrest. [mature spermatozoa are almost totally absent]. The photomicrograph shows a seminiferous tubule, sertoli cells, spermatogonia (curved arrow), spermatocytes (straight arrow) and spermatids (arrow head). Mature viable spermatozoa are almost completely absent.

DISCUSSION

The mobile phone users are exposed to different frequencies in different countries and continents. Exposure of radiofrequency energy depends upon the frequency of the cellular phone. The electromagnetic field radiation generated by mobile phones can possibly affect the reproductive function via three mechanisms: an EMW-specific effect; a thermal molecular effect; or a combination of both effects.⁸ Animal model studies show that electromagnetic field radiations generated by mobile phones have a wide range of damaging effects on the male reproductive system and sperm parameters.⁸ Moreover, mobile phone radiation decrease the serum level of hormones which are essential for spermatogenesis. In the present study it was found that long-term use of GSM mobile phone can cause hypospermatogenesis and maturation arrest in spermatozoa in the testis of Wistar albino rats compared to their matched control.

At high intensities, RF radiation has heating properties leading to thermal effects, increase in tissue or body temperature on exposure to EMFR can cause reversible disruption of spermatogenesis.¹⁴ Wang *et al.* suggested that Leydig cells are among the most susceptible cells to EMFR and injury to these cells may affect the spermatogenesis.¹⁵ As Leydig cells produce spermatozoa, if the Leydig cells are damaged, ultimately affect the spermatogenesis.¹⁶ Ozguner *et al.* demonstrated a decrease in seminiferous tubular diameter and epithelium thickness after applying a radio-frequency generator of 869-894 MHz.¹⁶ Similarly, Dasdag *et al.* found that using a conventional cellular telephone that was active for 3 minutes daily during 30 days decreased in mean seminiferous tubular diameter in the testes in rats.¹² It has also been reported that exposure to EMFR and mild scrotal heating can induce DNA damage in mammalian spermatozoa. Lai and Singh first reported DNA strand breaks from low intensity microwave RF radiation.¹⁷ In their study, 2 hours exposure to 2450 MHz continuous and pulsed RF radiation produced a dose-dependent increase in DNA single and double-strand breaks.

Aitken *et al.* suggested that radiofrequency EMW might have a genotoxic effect on epididymal spermatozoa and they found notable damage to mitochondrial and nuclear genome in epididymal spermatozoa of mice with RF EMW, 900 MHz, 12 hours a day for 7 days.¹⁸ Spermatozoa are extremely vulnerable to induction of DNA damage as they lose their cytoplasm, which contains anti-oxidant enzymes and their capacity for DNA repair after spermiation. Salama *et al.* conducted a study on the effects of exposure to a mobile phone on the testicular function and structure in adult rabbit.¹⁹ They reported a fall in the sperm concentration appeared in the phone group at week 6 and it became

statistically significant with increased duration of exposure from week 6 to week 8 compared with the two control (stress and ordinary) groups.¹⁹ Moreover, there was a more significant decline in the motile sperm population. Histological examination showed a significant decrease in the diameter of seminiferous tubules in the phone group compared to the stress and ordinary controls.

Davoudi *et al.* found that using GSM phones for 6 hours/day for 5 days decreased the rapid progressive motility of sperm cells.²⁰ The present results are in accordance with all these findings. Ashok *et al.* suggested that the use of cell phones is associated with a decrease in semen quality.²¹ The decrease in sperm count, motility, viability, and normal morphology is related to the duration of exposure to cell phones. Similarly, in the present animal model study, hypospermatogenesis and maturation arrest in the spermatozoa was found in Wistar albino rats. Wdowiak *et al.* conducted a study to determine the effects of the usage of cellular phones on the fertility in male subjects.²² They analyzed the effects of GSM mobile phone on the semen and it was noted that an increase in the percentage of sperm cells of abnormal morphology is associated with the duration of exposure to the waves emitted by the GSM phone. Researchers also investigated the effects of mobile phone radiation on the various hormones such as serum testosterone, follicular stimulating hormone (FSH), thyroid stimulating hormone (TSH) and thyroid hormone (T3,T4). Koyu *et al.* suggested that 900 MHz EMF emitted by cellular telephones decrease the serum TSH and T3-T4 levels.²³ More recently, Meo *et al.* investigated the effects of EMFR generated by mobile phones on serum testosterone levels in Wistar albino rats.²⁴ They found that exposure to mobile phone radiation for 60 minutes/day for the total period of 3 months significantly decreases the serum testosterone level in albino rats compared to their matched control. It is very obvious that mobile phone radiation affects the reproductive morphology as well as vital hormones such as serum testosterone and FSH at least in animals. These hormones are essential to spermatogenesis and maturation of the spermatozoa.^{25,26} In the present study we found hypospermatogenesis and maturation arrest in the spermatozoa in the testes of Wistar albino rats. This effect is most probably due to hormonal impairment caused by EMFR.

CONCLUSION

Long-term exposure to mobile phone radiation can cause hypospermatogenesis and maturation arrest of spermatozoa in the testis of albino rats.

Acknowledgement: This work was supported by grant 05-493, College of Medicine Research Centre (CMRC),

King Saud University, Riyadh, Kingdom of Saudi Arabia. We are thankful to the Deanship of Scientific Research, KSU, Director CMRC and technical staff Animal House, College of Medicine, KSU.

REFERENCES

1. Colonna A. [Cellular phones and cancer: current status]. *Bull Cancer* 2005; **92**:637-43. French.
2. Info Balt. More than four billion mobile phone users worldwide [Internet]. [updated 2010] Available from: <http://www.infobalt.it/main.php?&a=0&i=7983>
3. 98 Million mobile phone users in Pakistan [Internet]. [updated 2010]. Available from: <http://www.tauxeef.com/98-million-mobile-phone-users-in-pakistan>
4. Dindic B, Sokolovic D, Krstic D, Petkovic D, Jovanovic J, Muratovic M. Biochemical and histopathological effects of mobile phone exposure on rat hepatocytes and brain. *Acta Medica Medianae* 2010; **49**:37-42.
5. Maier M, Blakemore C, Koivisto M. The health hazards of mobile phones. *Br Med J* 2000; **320**:1288-9.
6. Kleinlogel H, Dierks T, Koenig T, Lehmann H, Minder A, Berz R. Effects of weak mobile phone-electromagnetic fields GSM UMTS on well-being and resting EEG. *Bioelectromagnetics* 2008; **29**:479-87.
7. British Medical Association Board of Science and Education. Mobile phones and health: an interim report [Internet]. [updated 2007 Oct 16]. Available from: http://www.bma.eu/sc/health_promotion_ethics/environmental_health/ScienceMobilePhonesInterim.jsp
8. Derias EM, Stefanis P, Drakeley A, Gazvani R, Lewis-Jones DI. Growing concern over the safety of using mobile phones and male fertility. *Arch Androl* 2006; **52**:9-14.
9. D'Andrea JA, Emmerson RY, Bailey CM, Olsen RG, Gandhi OP. Microwave radiation absorption in the rat: frequency-dependent SAR distribution in body and tail. *Bioelectromagnetics* 1985; **6**:199-206.
10. Al-Khalaiwi T, Meo SA. Association of mobile phone radiation with fatigue, headache, dizziness, tension and sleep disturbance in Saudi population. *Saudi Med J* 2004; **25**:732-6.
11. Meo SA, Al-Drees AM. Mobile phone related hazards and subjective hearing and vision symptoms in the Saudi population. *Int J Occup Med Environ Health* 2005; **18**:53-7.
12. Dasdag S, Ketani MA, Akdag Z, Ersay AR, Sari I, Demirtas OC, et al. Whole-body microwave exposure emitted by cellular phones and testicular function of rats. *Urol Res* 1999; **27**:219-23.
13. Mailankot M, Kunnath AP, Jayalekshmi H, Koduru B, Valsalan R. Radio frequency electromagnetic radiation (RF-EMR) from GSM (0.9/1.8GHz) mobile phones induces oxidative stress and reduces sperm motility in rats. *Clinics [Sao Paulo]* 2009; **64**:561-5.
14. Jung A, Schill WB. [Male infertility: current life style could be responsible for infertility]. *MMW Fortschr Med* 2000; **142**:31-3. German.
15. Wang SM, Wang DW, Peng RY, Gao YB, Yang Y, Hu WH, et al. [Effect of electromagnetic pulse irradiation on structure and function of Leydig cells in mice]. *Zhonghua Nan Ke Xue* 2003; **9**: 327-30. Chinese.
16. Ozguner M, Koyu A, Cesur G, Ural M, Ozguner F, Gokcimen A, et al. Biological and morphological effects on the reproductive organ of rats after exposure to electromagnetic field. *Saudi Med J* 2005; **26**:405-10.
17. Lai H, Singh NP. Single- and double-strand DNA breaks in rat brain cells after acute exposure to radiofrequency electromagnetic radiation. *Int J Radiat Biol* 1996; **69**:513-21.
18. Aitken RJ, Bennetts LE, Sawyer D, Wiklendt AM, King BV. Impact of radio frequency electromagnetic radiation on DNA integrity in the male germline. *Int J Androl* 2005; **28**:171-9.
19. Salama N, Kishimoto T, Kanayama HO. Effects of exposure to a mobile phone on testicular function and structure in adult rabbit. *Int J Androl* 2010; **33**:88-94. Epub 2009 Dec 2.
20. Davoudi M, Brossner C, Kuber W. The influence of electromagnetic waves on sperm motility. *Urol Urogynaecol* 2002; **19**:18-22.
21. Agarwal A, Deepinder F, Sharma RK, Ranga G, Li J.. Effect of cell phone usage on semen analysis in men attending infertility clinic: an observational study, *Fertil Steril* 2008; **89**:124-8. Epub 2007 May 4.
22. Wdowiak A, Wdowiak L, Henryk W. Evaluation of the effect of using mobile phones on male fertility. *Ann Agric Environ Med* 2007; **14**:169-72.
23. Koyu A, Cesur G, Ozguner F, Akdogan M, Mollaoglu H, Ozen S. Effects of 900 MHz electromagnetic field on TSH and thyroid hormones in rats. *Toxicol Lett* 2005; **157**:257-62. Epub 2005 Apr 11.
24. Meo SA, Al-Drees AM, Sufia H, Khan MM, Imran MB. Effects of mobile phone radiation on serum testosterone in Wistar albino rats. *Saudi Med J* 2010; **32**:179-83.
25. Walker WH. Non-classical actions of testosterone and spermatogenesis. *Philos Trans R Soc Lond B Biol Sci* 2010; **365**: 1557-69.
26. Kliesch S. Testosterone and infertility. *Urologe Artz* 2010; **49**:32-6.

.....★.....